



Pat. Name	Ms. MRS.SELVI	Age:	31
Ref. Dr.	Dr.	Date:	5/31/2007
Clinical Details:	--		

## OBSTRETICS III TRIMESTER SCAN REPROT

Single live fetus with head in the lower pole with longitudinal lie.

Fetal cardiac pulsation seen well and HR – 140 /min

### Fetal Biometry:

Parameter	Measurement (mm)	GA
BPD	69	26w4d
HC	254	27w6d
AC	231	28w2d
FL	53	27w4d

### Biometry Calculations: (LMP = 11/14/2006 )

	GA	EDD
Ultrasound	27w4d	8/26/2007
Menstrual	28w2d	8/21/2007

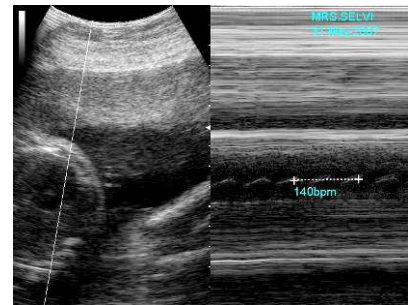
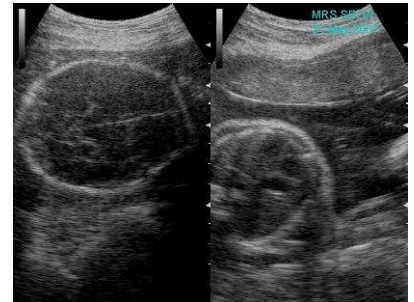
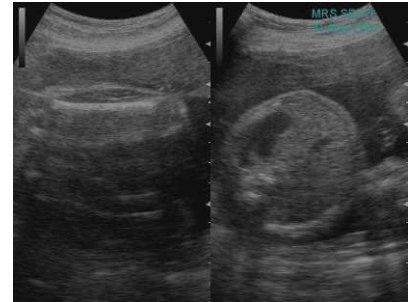
- Fetal intracranium, stomach, kidneys, spine, and urinary bladder are normal. Fetal limbs, to the extent visualised appear normal. No evidence of gross congenital anomalies.
- Fetal movements are normal.
- . Four chambered view of the heart is normal.
- Placenta has grade 1 maturity and is in anterior upper segment.
- There is no evidence of placenta praevia.
- Amniotic fluid is adequate in quantity.
- Cord shows 3 vessels.
- Cervix is normal

## IMPRESSION

1. Single live foetus in cephalic presentation and longitudinal lie with gestational age of 27w4d corresponding to dates.

2. Approximate fetal weight 1118gm

### USG Images



DR.R.SEN, MBBS.,DMRD  
Radiologist